Enteroscopy in Inflammatory Bowel Disease

Dr. Elizabeth Odstrcil
Digestive Health Associates of Texas
April 22, 2017

But…..

- Capsules fail to reach the cecum in as many as 25% of patients
- Patients with known CD have a risk of capsule retention of 6-13%
- Only recently has there been diagnostic criteria for the diagnosis of Crohn's disease
  - Lewis score and CECDAI
  - Most people used > 3 ulcerations in the absence of NSAIDs

Thus the Development of Deep Enteroscopy

Small Bowel Endoscopy

- Any endoluminal examination of the small bowel, including capsule endoscopy, push enteroscopy, balloon and device assisted enteroscopy
- SB involvement in Crohn's disease occurs in up to 60% of patients; nearly 30% have isolated SB disease

Why is Enteroscopy so Important?

- Histological confirmation is important
- Recently validated criteria for reporting findings and confirming dx of Crohn's on capsule endoscopy
- Multiple things can mimic Crohn's on capsule endoscopy including NSAID enteropathy, infections, or malignancy
- Endoscopic remission is becoming the goal of therapy and enteroscopy may have a role in assessment

Capsule Endoscopy

- Useful in patients with high clinical suspicion of CD despite negative radiological and conventional endoscopy
- Prospective study showed superiority of CE over standard small bowel imaging
- Can be used in established CD with unexplained symptoms like persistent anemia, abdominal pain, or malabsorption
  - Strictures should be excluded before CE
- Normal CE has a high negative predictive value for active CD

Guidelines (OMED ECCO)

- Device assisted enteroscopy can be used if:
  - Conventional studies, including ileocolonscopy and radiographic imaging, have been inconclusive
  - Histological diagnosis would alter disease management
  - Therapeutic maneuvers are required

Bourreille A, et al. Role of small-bowel endoscopy in the management of patients with inflammatory bowel disease: an international OMED-ECCO consensus. Endoscopy 2009;41:618-637

Advantages of Enteroscopy

- Real time viewing of the small bowel
- Ability to sample the small bowel
- Ability to perform therapeutic interventions such as:
  - Dilation with TTS balloons
  - Hemostasis
  - Polypectomy
  - Stent insertion
  - Tattoo of lesions allowing targeted surgical intervention
  - Retrieval of foreign bodies (i.e. capsule endoscopy)

Double Balloon Enteroscopy

- Developed in 2001 by Prof Yamamoto
- Inflatable balloon allows better mucosal grip of the enteroscope and the overtube helps to stabilize position within the lumen
- Push-pull technique
- Surprisingly a-traumatic
- Most therapeutic maneuvers possible
- Short learning curve for most accomplished, patient endoscopists!

Endoscopic Findings of Crohn's Disease during DAE

Endoscopic finding	Description
aphthoid ulcer	small, shallow depressed lesion with loss of villi
longitudinal ulcer	typical Crohn ulcers, usually occurring on the mesenteric side of the intestine
cobblestone appearance	result of inflammatory changes and edema in the mucosa left by ulcers
stricture	repeated formation and healing of ulcers causes cicatricial contraction of the intestinal mucosa
fistula	usually occurs proximal to a stricture
pseudo-diverticulum	multiple strictures may lead to the formation of pseudo-diverticula
neoplastic lesions	both adenocarcinoma and lymphoma may occur in intestinal CD

Moreels, TG. Small bowel enteroscopy in Crohn' s disease. Annals of Gastro 2012;25:14-20.

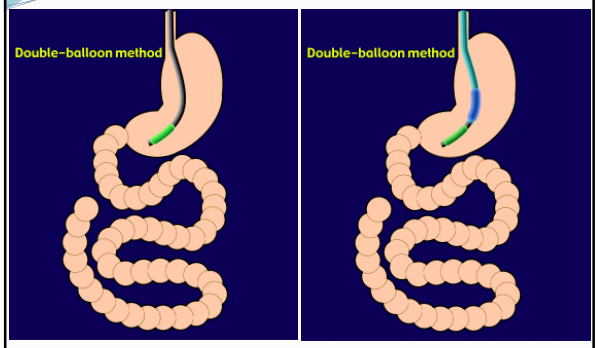

DOUBLE BALLOON ENDOSCOPY

Currently Available Tools

- Push enteroscopy – has working channel of 220-250cm
  - Allows visualization of proximal small bowel, usually up to about 100 cm distal to the Ligament of Trietz
  - Can also use a pediatric colonoscope
  - Widely available
  - Largely replaced now by balloon-assisted techniques

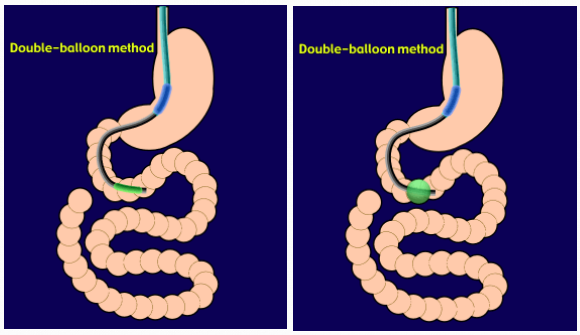

DOUBLE BALLOON ENDOSCOPY

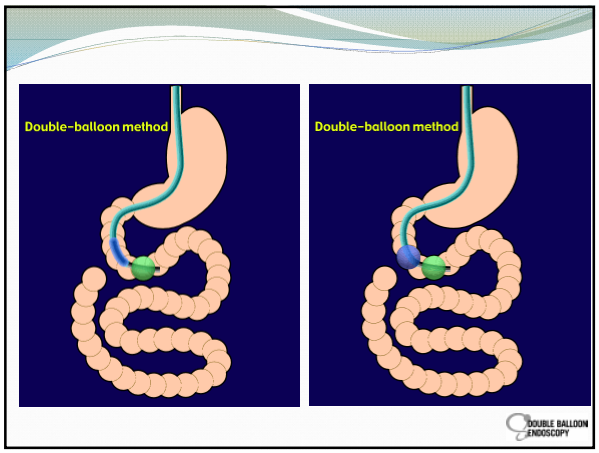
Double-balloon method

Double-balloon method

DOUBLE BALLOON ENDOSCOPY

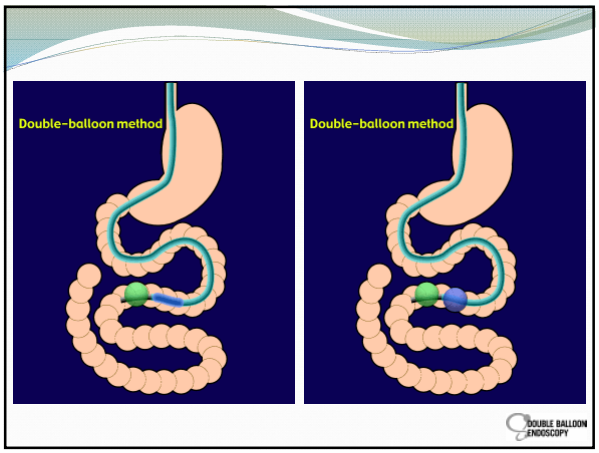
Double-balloon method

Double-balloon method

DOUBLE BALLOON ENDOSCOPY

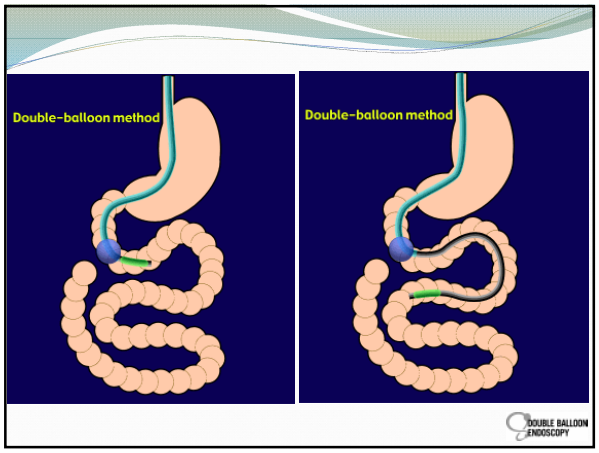
Double-balloon method

Double-balloon method

DOUBLE BALLOON ENDOSCOPY

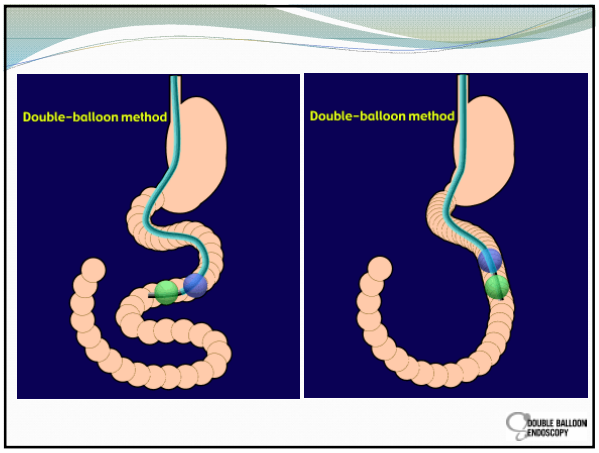
Double-balloon method

Double-balloon method

DOUBLE BALLOON ENDOSCOPY

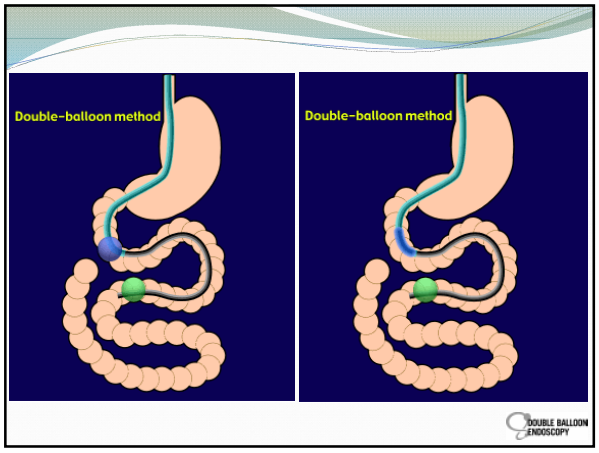
Double-balloon method

Double-balloon method

DOUBLE BALLOON ENDOSCOPY

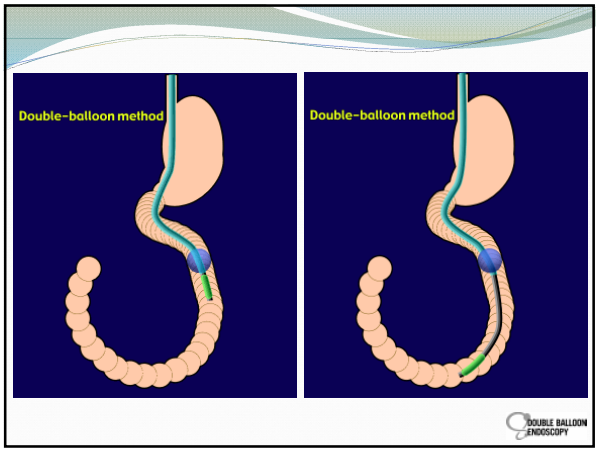
Double-balloon method

Double-balloon method

DOUBLE BALLOON ENDOSCOPY

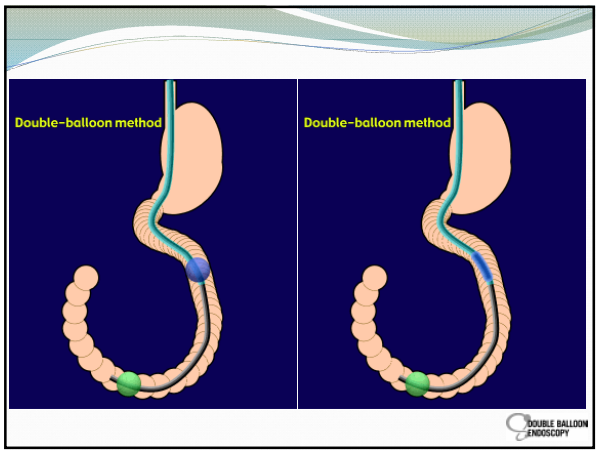

Single Balloon Enteroscopy

- Second on the scene
- Silicone balloon (not latex) on a flexible overtube
- Push and pull technique
- Also a-traumatic
- Most therapeutic maneuvers possible
- Short learning curve
- Seems to get a good exam 50-70% of the time
- Less set up time, less confusion
  - Only one balloon to worry about

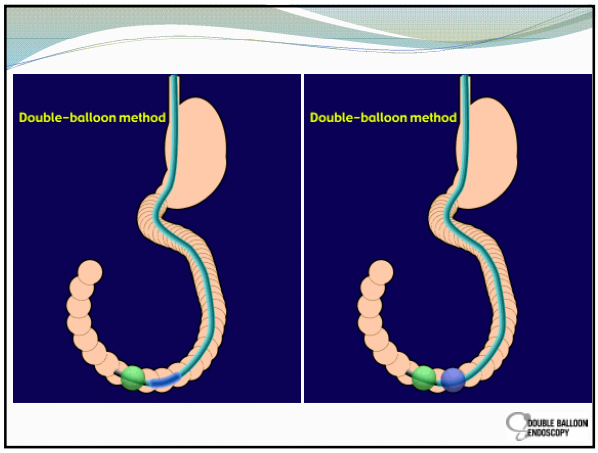

Spiral Enteroscopy

- Another overtube based method
- A raised spiral attached to a locking overtube (118 cm long)
- Scope is advanced by rotating the overtube and bowel is actually pleated on to the overtube
- Allows rapid and deep intubation of the small bowel
- Spiral, rotational technique

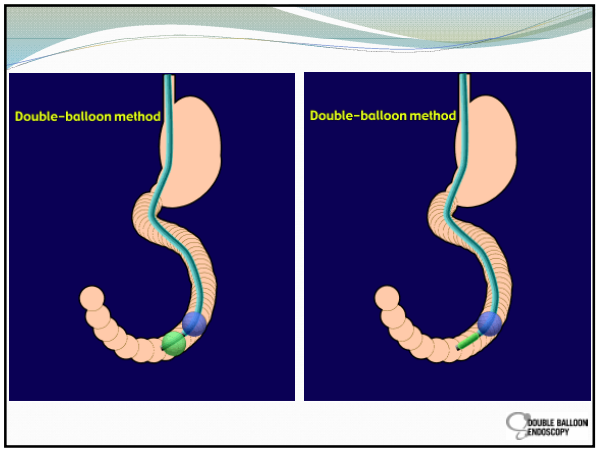

DBE in Crohn's Management

- 5 large tertiary DBE centers in the US from 2004-2009
- 98 procedures in 81 patients with known (38) or suspected (43) Crohn's disease
- Indications: bleeding, abnormal imaging, abdominal pain, stricture, diarrhea, retained capsule
- Diagnostic yield = 83% overall
- In known Crohn's patients, yield = 87%
  - Recurrent Crohn's disease confirmed (11/38)
  - CD stricture (5/38)
  - Exclusion of Crohn's disease (9/38)
  - Non-specific ulceration (2/38)
  - Anastomotic ulceration (3/38)
  - Function obstructions (3/38)
- DBE impacted management in 79% of patients (in known CD it was 82%)
- DBE was safe – (1 fever and 1 perforation)

Rahman A, et al. Double balloon enteroscopy in Crohn' s disease: findings and impact on management in a multicenter retrospective study. Gastrointest Endosc 2015;82:102-107.

Safety of Deep Enteroscopy

- Adverse event rate of 1% for diagnostic exams in Crohn's Disease (similar for other indications)
- Main complications are sedation risks, bleeding, pancreatitis, and perforation

Abnormal Capsule Findings

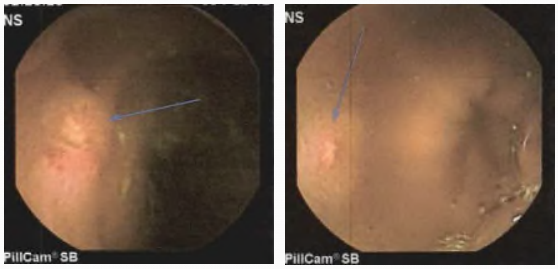

How does DAE compare to other Modalities?

- DAE versus capsule endoscopy
  - Incomplete small bowel visualization occurs in up to 30% of CE investigations
  - Studies comparing CE to DBE have shown significant small bowel abnormalities missed on capsule

Evaluation of Prior Ileostomy Site in a Patient s/p IPAA

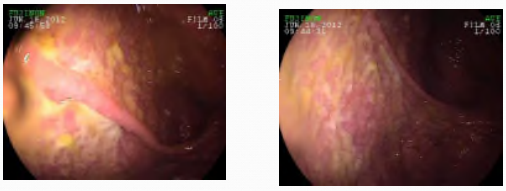

Path = Acute and chronic enteritis

BUMC Experience of Deep Enteroscopy in IBD

Recurrent pSBO in Patient with Normal CT and Normal SBFT

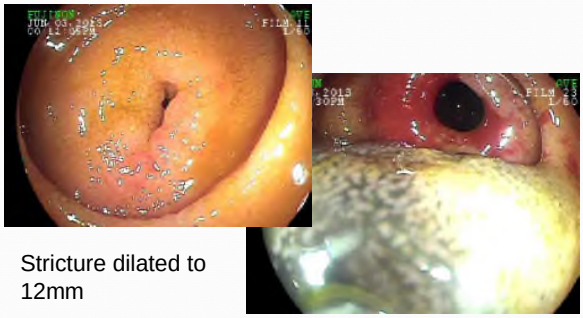

Stricture dilated to 12mm

Stricture Dilation

- Balloon enterosocpy with stricture dilation has a reported perforation risk of 0-3%
- Comparable to risk of dilation of colonic strictures
- Single center in Australia
  - 15 patients with 25 dilations – 10 with Crohn's disease
  - 80% had clinical improvement after dilation
  - Complication rate was 8% with 2 perforations – both in patients with Crohn's (both had strictures with mild ulceration and were dilated to 15mm)

Gill RS and Kaffes AJ. Small bowel stricture characterization and outcomes of dilation by double balloon enteroscopy: a single-center experience. Ther Adv Gastroenterol 2014; 7(3):108-114.

Baylor University Medical Center at Dallas

BaylorScott&White HEALTH

A Novel Motorized Spiral Enteroscope Technology Reveals Meckel's Diverticulum

Rosemary Nustas, MD, Daniel DeMarco, MD, FACG, Elizabeth Odstrcil, MD, FACG

Introduction

Gastrointestinal bleeding is a major cause of emergency hospital attendance in adults.

Nearly 80% of this bleeding in adults originates proximal to the ligament of Treitz.

The most common source of the lower gastrointestinal bleeding is colon, with less than 5% of bleeding from small intestine.

The usual investigations include upper gastrointestinal endoscopy and colonoscopy as well as the usual biochemical and hematological investigations.

Technetium-bleeding scan and angiography may be used to diagnose non focal sources of bleeding such as Meckel's diverticulum.

We present a case of obscure small bowel bleeding diagnosed with a novel motorized spiral enteroscope that achieved total enteroscopy.

Case Presentation

A 23 year-old white male with no significant past medical history presented with recurrent red blood per rectum. In the past, he had a total of 5 colonoscopies and 3 EGDs and a PillCam SBE study but all have been unremarking. He has never had hematemesis or melena. Denies NSAIDs use.

This episode started 3 weeks ago when he had a large episode of painless hematochezia that continued for about 3 days.

ROS negative except as mentioned in HPI

Past history: recurrent GI bleeding, underwent procedures as mentioned in HPI

Social history: Denies tobacco, ETOH or illicit drug use.

Family history: No IBD or known GI diseases or cancers.

Allergies: No known allergies.

Medications: No NSAIDs or OTC medications. Not on any regular medications.

Case Presentation (Continued)

Vital signs: BMI 20, BP 102/66, HR 67, Temp 97.2

Pertinent physical exam:

General: pleasant, well developed male, no obvious pallor, not in acute distress.

Chest: clear, good air entry bilaterally.

Heart: No JVD, regular S1, S2, no obvious murmurs.

Abdomen: soft, non tender, non distended, + bowel sounds, no palpable organs or masses.

Rectal exam: no blood, no external hemorrhoids or anal fissure.

Neuro: grossly intact.

Course of events:

He was admitted with symptomatic anemia and was given 5 units of PRBCs. Hgb was 10.7 at that time. DCE was unremarking. Colonoscopy showed blood in the cecum and distal ileum but no active site of bleeding. The distal 10cm of ileum was examined. Shortly after colonoscopy, he underwent a CT angiogram that was negative and the next day had a tagged RBC scan that was also negative.

Subsequently, he was discharged and underwent outpatient lower device assisted double balloon enteroscopy that was negative. DBE on proximal to ileocecal valve was examined.

He then consented for the Motorized Spiral study and underwent device assisted upper total enteroscopy that revealed Meckel's Diverticulum in the distal ileum.

Two days after the total enteroscopy, the patient presented with further hematochezia. His hemoglobin was 8.8. He underwent an uneventful laparoscopic Meckel's diverticulectomy which revealed a large Meckel's diverticulum with gastric mucosa and ulceration. He has had no further bleeding.

Discussion

Motorized Spiral image. Diverticulum (arrow) seen during spiral device assisted enteroscopy

Motorized Spiral image. Colon

Conclusion

The motorized spiral enteroscope is a promising new technology that can achieve complete enteroscopy with relative ease and a short procedure time compared to other modalities. We suspect that the Meckel's diverticulum was not visualized using several techniques including retrograde double balloon approach due to the angle of the Meckel's lumen. In this case, the motorized spiral technique achieved complete enteroscopy in 78 minutes with insertion time to the cecum of 50 minutes. This device is currently being studied in a large multicenter randomized trial and is expected to be available for use in the near future, eliminating the previous intra-efficient techniques.

Meckel's diverticulum is the most common congenital abnormality of the intestinal tract, affecting 2% of the population, 2% present in 2% population, 2% from the ileo-cecal junction, and 2% in the

It usually remains asymptomatic throughout a patient's lifetime.

Intestinal obstruction is the most common complication in the adult.

Diagnosis is difficult but is usually made by technetium-99m pertechnetate scan which is specific to ectopic gastric mucosa.

The treatment of choice for the symptomatic Meckel's diverticulum is the surgical resection.

Patient Failing Remicade Therapy for Crohn's – CT showing small bowel thickening

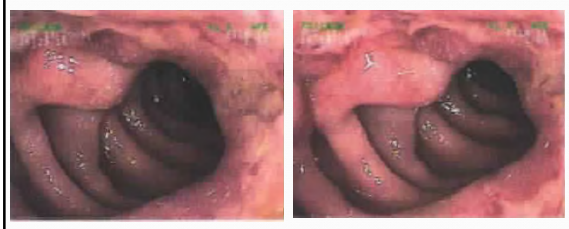

Path = Histoplasmosis

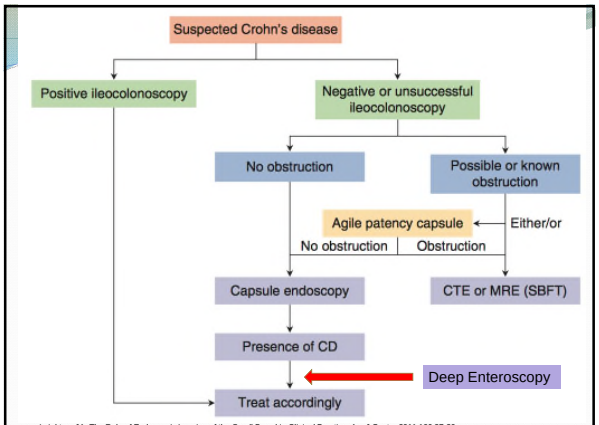

Leighton, JA. The Role of Endoscopic Imaging of the Small Bowel in Clinical Practice. Am J Gastro 2011;106:27-36.

Tools of the Future… Power Spiral

- Disassemble a pediatric colonoscope
- Insert a motor in the handle with a drive shaft down the insertion tube
- Different spiral configurations mounted on the scope
- Forward/reverse rotation controlled by a foot pedal
- Currently in clinical trials

Conclusion

- Although deep enteroscopy is invasive, it can be used safely as a complementary tool to capsule endoscopy and small bowel imaging for the diagnosis and management of Crohn's disease
- Larger, prospective trials comparing the different modalities, especially in Crohn's disease, are needed