Case Presentation: Dyspnea

T.G. Ellington, D.O.

Cardiovascular Disease Fellow, PGY-6

December 7, 2019

Initial Presentation

- 55 year old woman presents to the Emergency Department with a complaint of chest pain associated with shortness of breath
- Symptoms began in an argument with her husband
- Sudden onset, intermittent
- “Extreme tightness”, 7/10 intensity, substernal and nonradiating
- Shortness of breath has been progressing over several months with exertional chest pain
- Received 324 mg of aspirin by EMS
- Describes transient hemoptysis brought on with intense effort, specifically sexual activity

Past Medical History

- Hypertension
- Diabetes Mellitus
- Chronic Kidney Disease, stage 1
- Says she has had multiple MI in the past
- Reported h/o prior stress test with “bad” results
- Has seen cardiologist outside the system who told her she would need a pacemaker eventually for sinus bradycardia
- Told by cardiologist that “bottom right side of her heart was mush”

Past Surgical History

- Hysterectomy
- Tonsillectomy

Family History

- Mother and father with Heart Disease

Social History

- Current smoker, ½ pack per day
- Denies EtOh
- Occasionally uses cannabis and amphetamines

Examination

- BP 111/76 (BP Location: Left Arm, Patient Position: Lying) | **Pulse (!) 48** | Temp 97.5 °F (36.4 °C) | Resp 18 | Ht 162.6 cm (64") | Wt 86.6 kg (191 lb) | SpO2 97% | BMI 32.79 kg/m2
- GEN: well-developed, no acute distress, lying comfortably in bed
- HEENT: NC/AT; PERRL bilaterally, EOMI, no conjunctival injection or scleral icterus
- Neck: supple, no thyromegaly
- CV: Bradycardic, regular rhythm; Good S1, S2; **2/6 systolic murmur at the apex,** no rubs or gallops; no JVD; no carotid bruits; no lower extremity edema
- Lungs: clear to auscultation bilaterally, nonlabored, nontachypneic
- Abdomen: soft, nontender, nondistended; no hepatomegaly
- Extremities: radial pulses 2+ bilaterally, no lower extremity edema
- Musculoskeletal: no muscle atrophy or weakness noted
- Neuro: A&Ox3, moves extremities x 4
- Skin: no rashes or induration noted

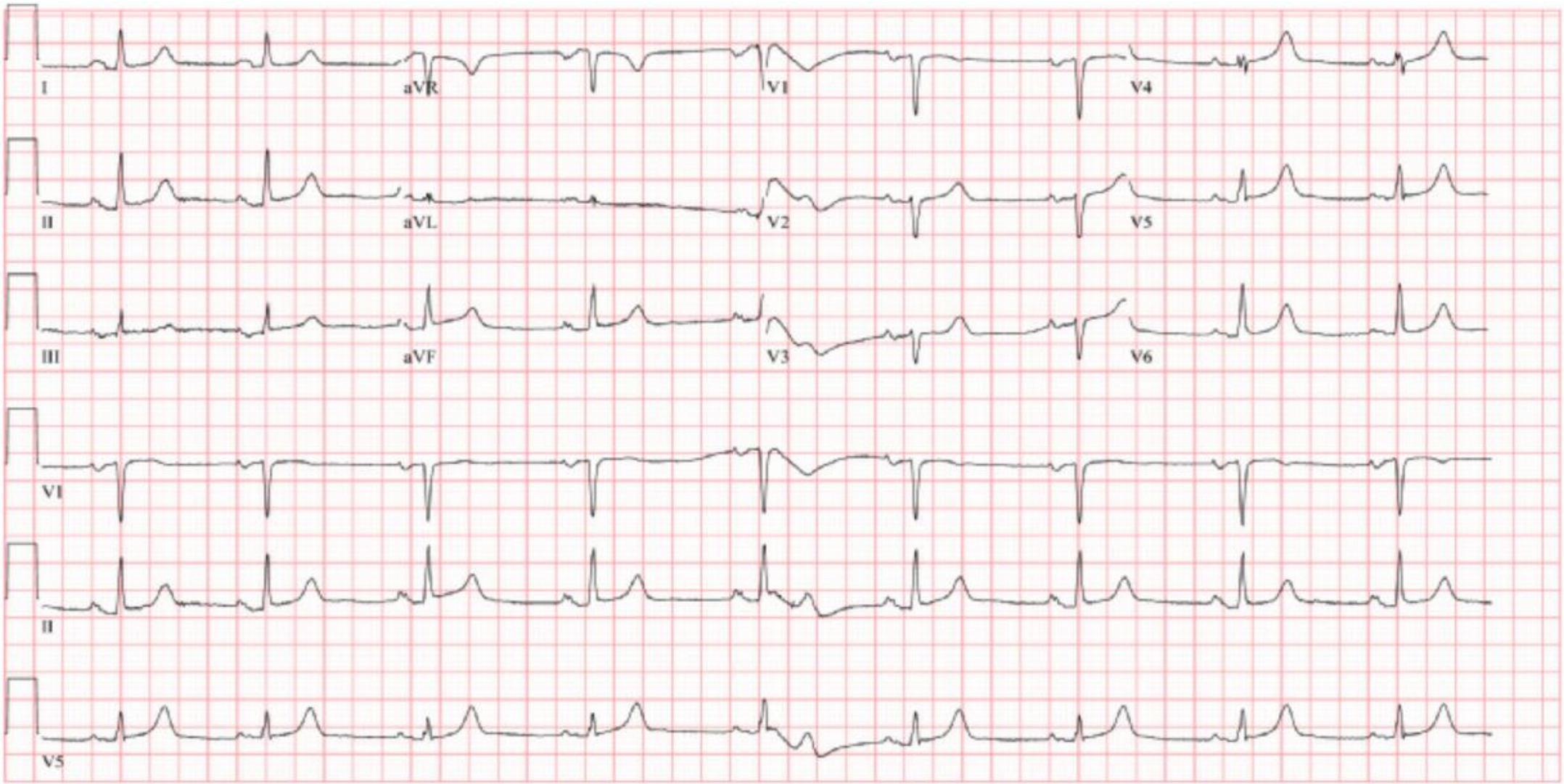
I
aVR
V1
V4
II
aVL
V2
V5
III
aVF
V3
V6
V1
II
V5

Lab

- WBC 8.9
- Hb 12.9
- BUN 34, Creatinine 1.78

- Troponin 0.03
- Brain Natriuretic Peptide 115
- D-Dimer 0.27
- Procalcitonin negative
- TSH 1.2
- Cholesterol 171, HDL 31, LDL 120

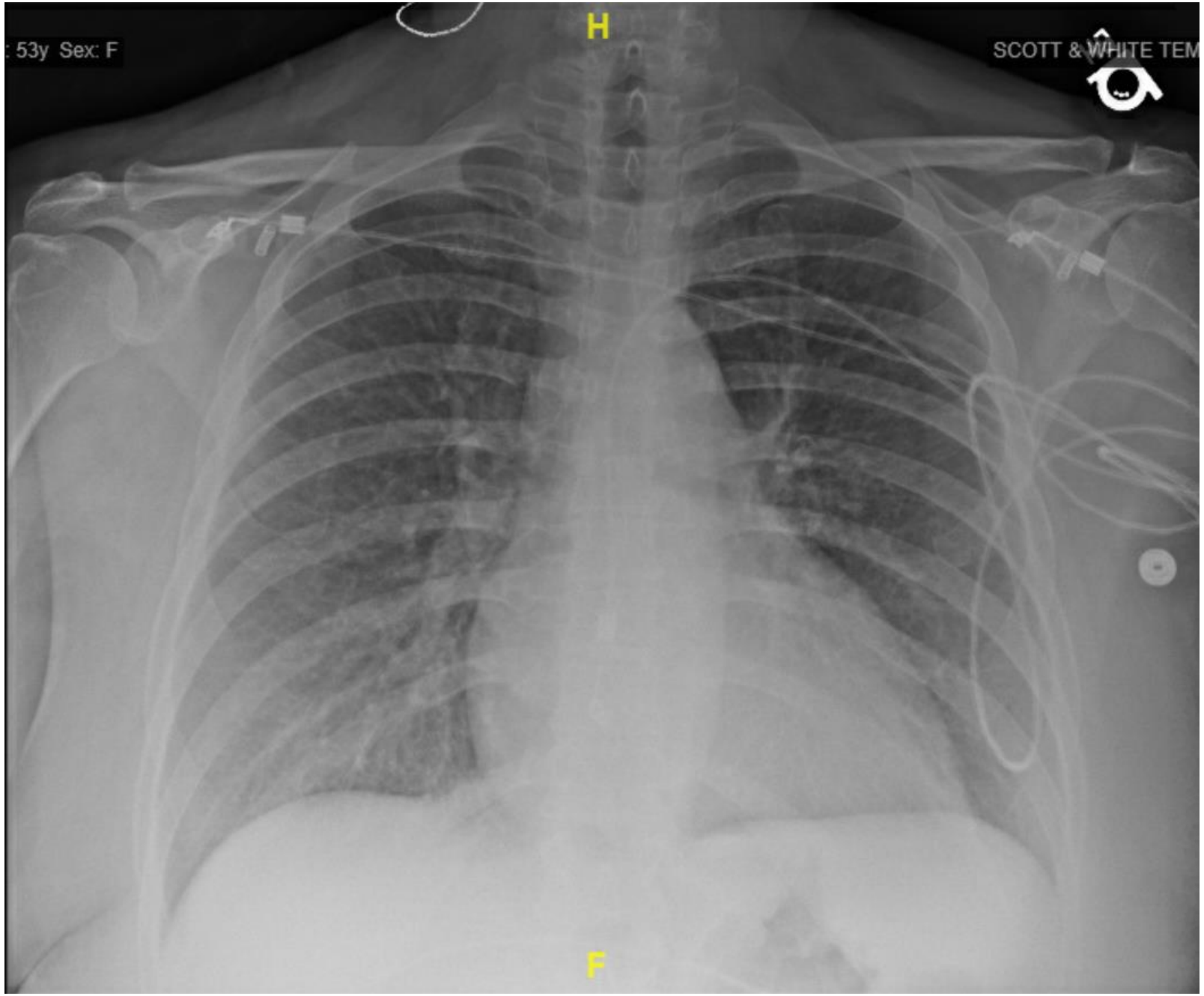
53y Sex: F
H
SCOTT & WHITE TEM
F

Chest X Ray

IMPRESSION: Borderline cardiac and pulmonary vascular prominence but without evidence of overt CHF or other definite acute process.

Chest CT without contrast

IMPRESSION:
Prominent cardiac silhouette with mitral annulus and/or valvular calcification.
Aortic atherosclerosis and coronary artery calcification.

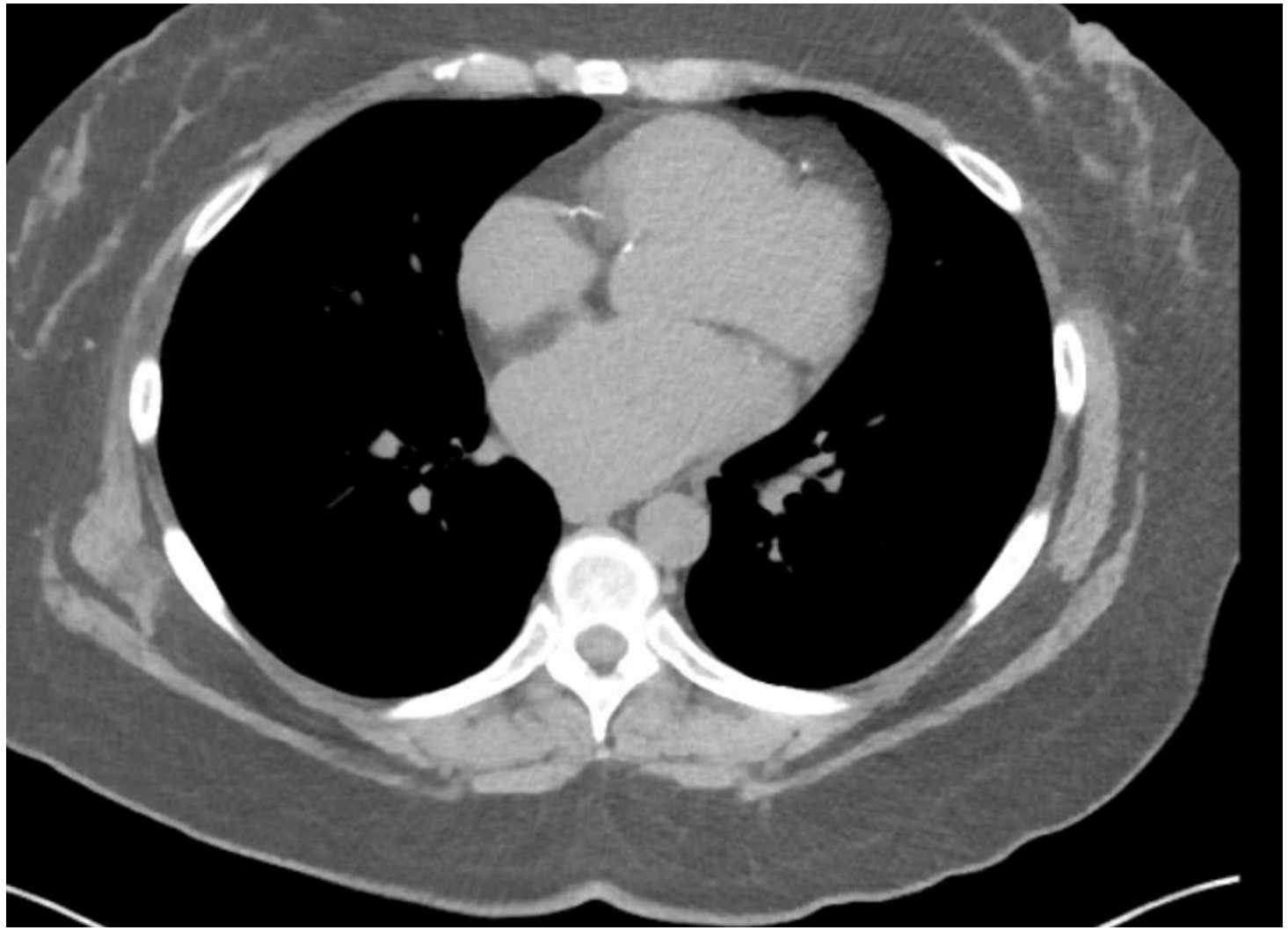

Transthoracic Echocardiogram

1. Normal left ventricular size with low normal global systolic function. Ejection fraction is calculated to be 50%.
2. Normal right ventricular size and function.
3. Moderate left atrial enlargement.
4. Severe mitral stenosis, most likely rheumatic, and likely moderate mitral regurgitation. Insufficient data to estimate RVSP and pulmonary pressures. Based on mitral valvular anatomy and degree of mitral regurgitation, not a percutaneous mitral balloon valvuloplasty (PMBV) candidate.

Mitral Valve Assessment by TTE

- Severe mitral valve stenosis.
- Severe thickening of both the anterior and posterior mitral valve leaflets extending into the chordal structures, which are significantly thickened.
- The leaflet tissue appears bright throughout.
- There is restricted movement of the anterior leaflet and minimal movement of the posterior leaflet.
- Mitral valve mean gradient is 7-11 mmHg at a heart rate of 45 bpm. MVA by PHT is 0.8 cm^2.
- MVA by planimetry 1.1-1.2. cm2.
- At least moderate mitral regurgitation.

Coronary Angiogram

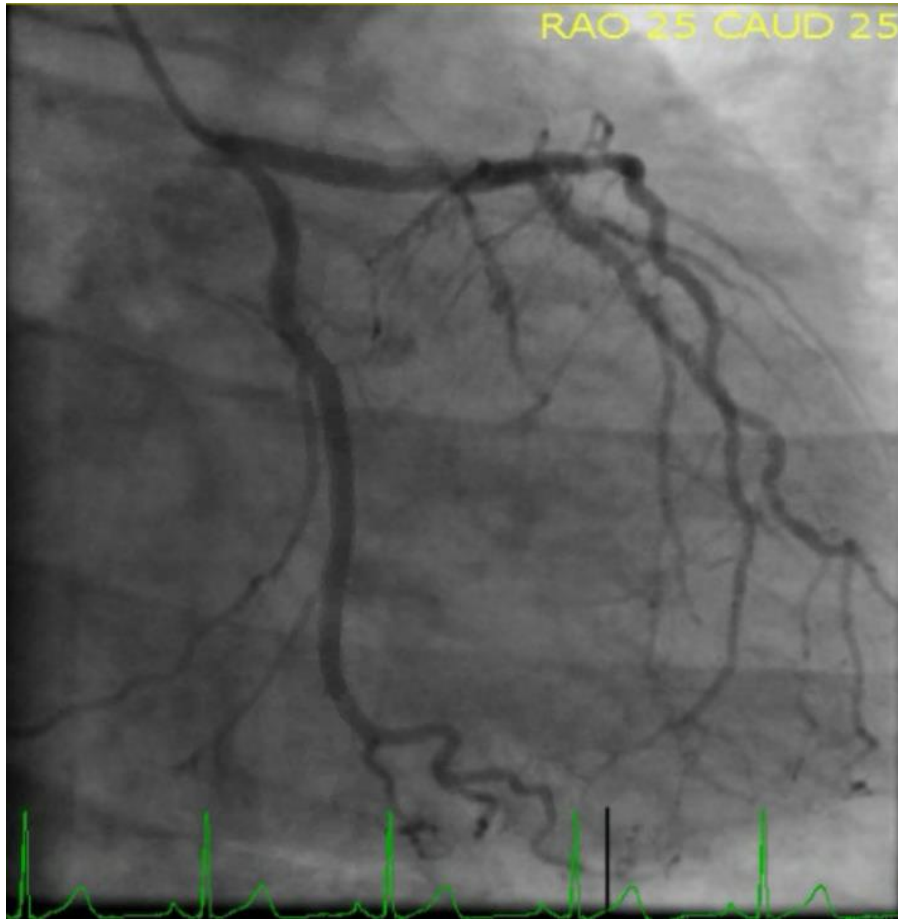

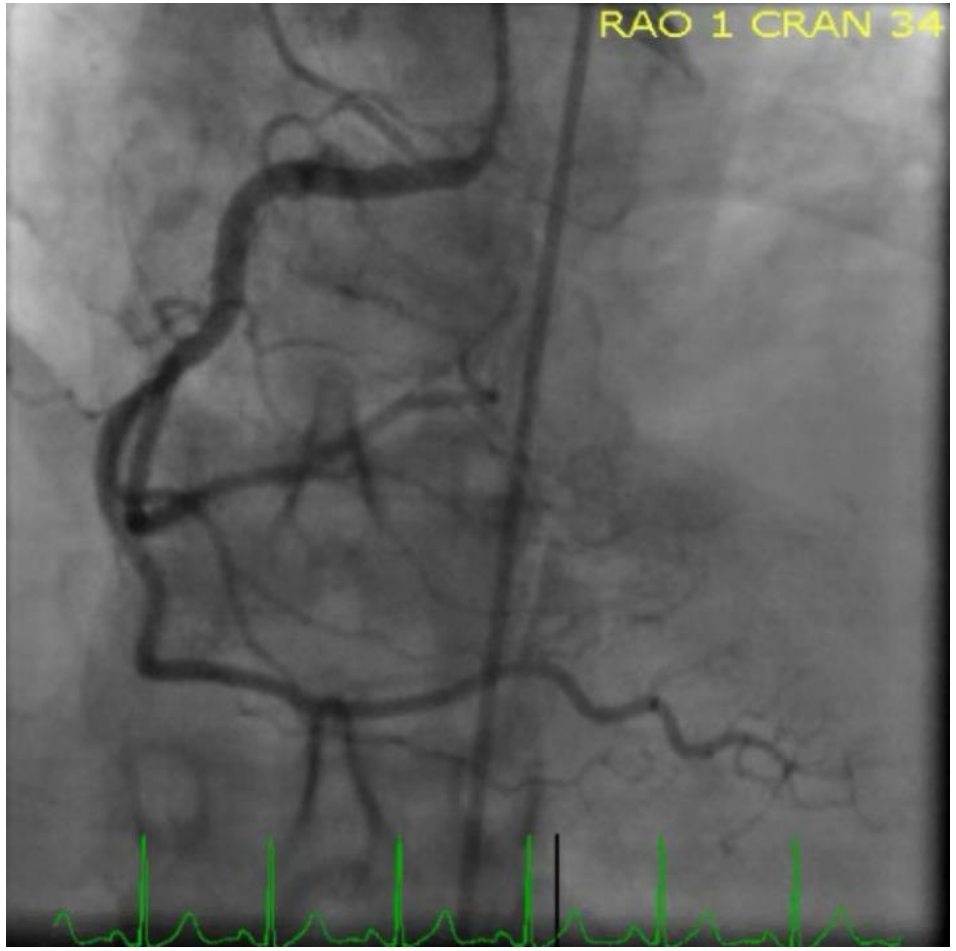

Right Heart Catheterization

• RA pressure	15 mm Hg
• Pulmonary artery (s/d/m)	58 / 33 / 44 mm Hg
• Pulmonary capillary wedge	41 mm Hg
• Pulmonary vasc resistance	35.93 dyne-sec cm-5
• Central aortic (s/d/m)	110/66/85
• Left ventricle (s/ed)	115/23
• Systemic vasc resistance	838.32 dyne-sec cm-5

Mitral valve: Mean gradient 18 mmHg; valve area: 1.22 cm2

Hospital Course

- Initially treated with IV furosemide and symptoms improved
- Variable HR as low as 30s and as high as 140s with worse symptoms
- Sent for Right Thoracotomy Mini Mitral Valve Replacement for Rheumatic Mitral Stenosis
  - 27-mm Carpentier-Edwards pericardial tissue valve
  - Complicated by Complete Heart Block post-operatively
  - Dual-chamber pacemaker implanted prior to discharge
- Takes full dose aspirin 325 mg daily

Follow-up

- Followed up in surgical clinic a few times asking for more pain medicine due to thoracotomy pain
- Not followed recently by CTS or Cardiology
- Further ED visits and admissions have been for non-cardiac issues